

Temple syndrome with atypical features: a case report

M. Yakoreva^{1,2}, T. Kahre^{1,2}, S. Pajusalu^{1,3}, T. Reimand^{1,2,3}, K. Õunap^{1,2}

¹ Tartu University Hospital, United Laboratories, Department of Genetics, Tartu, Estonia,

² Department of Pediatrics, Institute of Clinical Medicine, University of Tartu, Tartu, Estonia

³ Department of Biomedicine, Institute of Biomedicine and Translational Medicine, University of Tartu, Tartu, Estonia

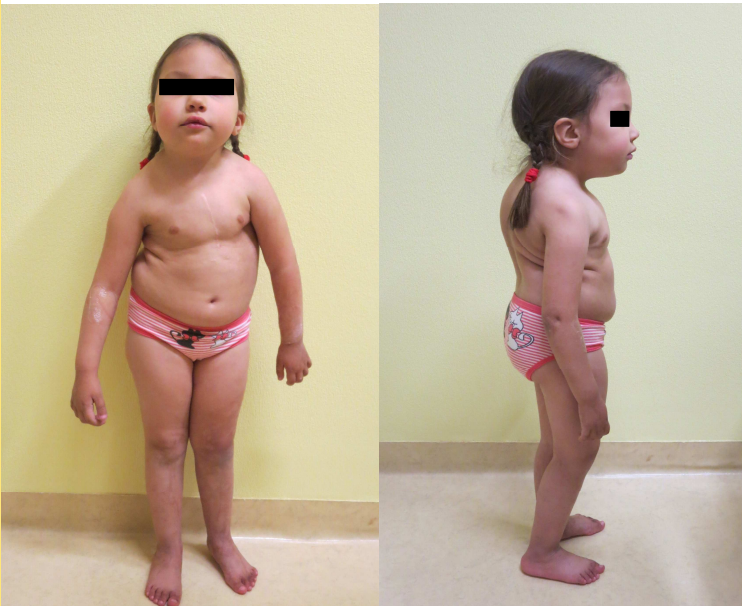Introduction

- Temple syndrome (TS) is a rare imprinting disorder described for the first time in 1991 by Temple et al. in a young male with balanced Robertsonian translocation (13;14) and maternal uniparental disomy of chromosome 14 [1].
- TS is characterized by prenatal and postnatal growth retardation, muscular hypotonia, poor feeding in the neonatal period, motor and developmental delay, scoliosis, premature puberty, truncal obesity, short adult stature, small feet and hands and some non-specific dysmorphic features such as almond-shaped eyes, broad nasal tip and tall forehead. IQ can be normal or mildly reduced [2].
- TS is caused by abnormal expression of genes at the imprinted locus 14q32. Maternal uniparental disomy of chromosome 14 (UPD(14)mat) is the underlying cause of TS. Isolated methylation defects and paternal deletions of imprinted locus 14q32 could be found in other TS cases [3].

Case presentation

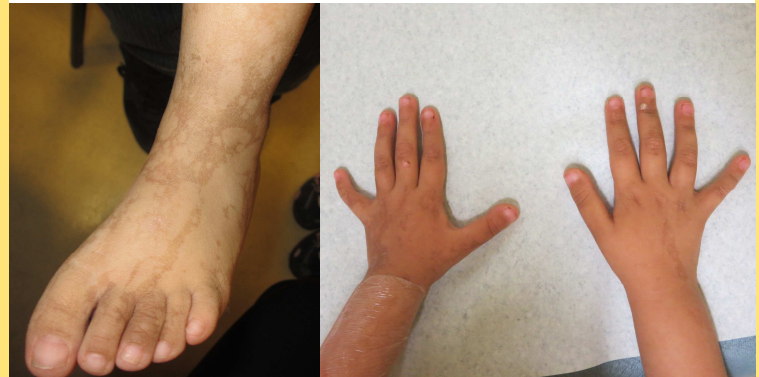- A 4-year-old girl was referred to genetic counseling because of congenital heart defect, developmental delay and dysmorphic features.
- The patient was born at the 35th weeks of gestation with weight 1832g (-1.5 SD) and length 42cm (-2 SD). Pregnancy was complicated by IUGR and oligohydramnios. At 20 weeks gestation, amniocentesis was performed and the karyotype of the fetus was found to be normal 46,XX.
- Shortly after the birth atrioventricular septal defect, congestive heart insufficiency and kyphoscoliosis were diagnosed. During the first years of life, the child had feeding difficulties, poor weight gain, hypotonia and severe psychomotor developmental delay.
- Chromosomal microarray (CMA) analysis revealed no copy number variants or uniparental isodisomy and the result of MS-MLPA analysis of the imprinted BWS/SRS region 11p15 was normal.

Fig. 1: The patient's appearance on frontal and lateral views



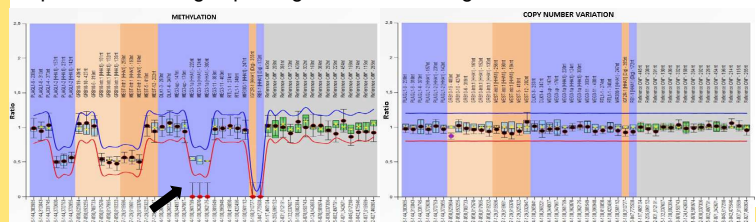
- Later, dysmorphic features, body asymmetry, increasing linear pigmentation on the arms and legs, hyperopia, strabismus, progressive scoliosis and cognitive delay were noted (Fig. 1-2). She started to walk independently at 2.5 years of age. Her height now is -5 SD, weight and OFC -2.5 SD.

Fig. 2: Linear hyperpigmentation on the hands and legs



- Whole exome sequencing analysis identified in the patient a compound heterozygous mutations, c.1408C>T (p.Arg470Cys) and c.1573C>G (p.Gln525Glu), in *CTCF* gene. Because the gene is suggested to participate in the establishment of methylation in imprinted genes, additional analysis of imprinted regions was performed.
- UPD7-UPD14 MS-MLPA analysis from whole blood DNA revealed a complete hypomethylation of *MEG3* gene in imprinted region 14q32.2 (Fig. 3). The same result was obtained using DNA from hyperpigmented and normal skin fibroblasts, urine and buccal swab. Comparative analysis of the SNPs using patient's and mother's CMA results showed maternal heterodisomy of the whole chromosome 14. No mosaicism for imprinting defects or trisomy 14 was detected.

Fig. 3: Results of MS-MLPA analysis. Three methylation specific probes detecting imprinting status of *MEG3* gene are shown with arrow



Conclusions

- Unlike previously described cases, our patient has more severe clinical presentation of TS with congenital heart defect, vision problems and skin pigmentation changes.
- The significance of detected *CTCF* gene mutations is not currently known and further studies are needed.
- This work was supported by the Estonian Research Council grant PUT355.

References

1. Temple IK, Cockwell A, Hassold T, Pettay D, Jacobs P. Maternal uniparental disomy for chromosome 14. *J Med Genet.* 1991 Aug;28(8):511-4.
2. Severi G, Bernardini L, Briuglia S, Bigoni S, Buldrini B, Magini P, et al. New patients with Temple syndrome caused by 14q32 deletion: Genotype-phenotype correlations and risk of thyroid cancer. *Am J Med Genet A.* 2016 Jan;170A(1):162-9.
3. Eggermann T, Perez de Nancraes G, Maher ER, Temple IK, Turner Z, Monk D, et al. Imprinting disorders: a group of congenital disorders with overlapping patterns of molecular changes affecting imprinted loci. *Clin Epigenetics.* 2015;7:123.